


PEDIATRIC EMERGENCIES

HISTORY RED FLAGS

CP + EXERTION



**SYNCOPE +
EXERTION**

ANOMALOUS CORONARY ARTERY

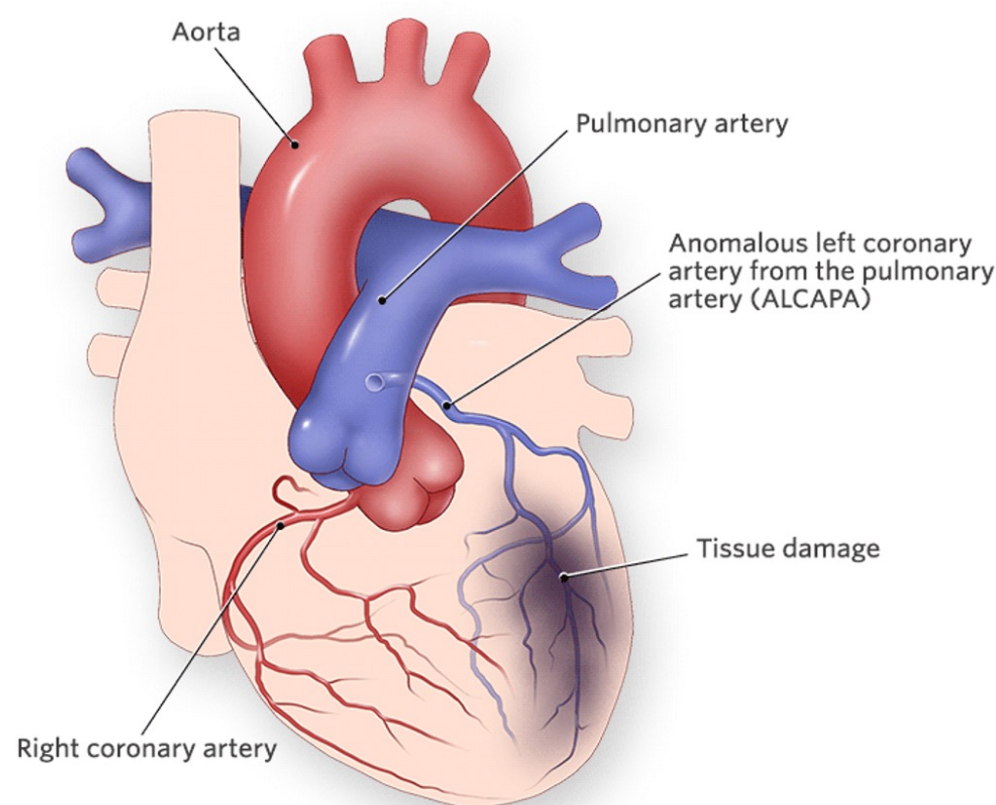
CP WITH EXERTION

**SYNCOPE WITH
EXERTION**

RCA >> LCA

LCA MORE LETHAL

STAT ECHO



PEDIATRIC EMERGENCIES

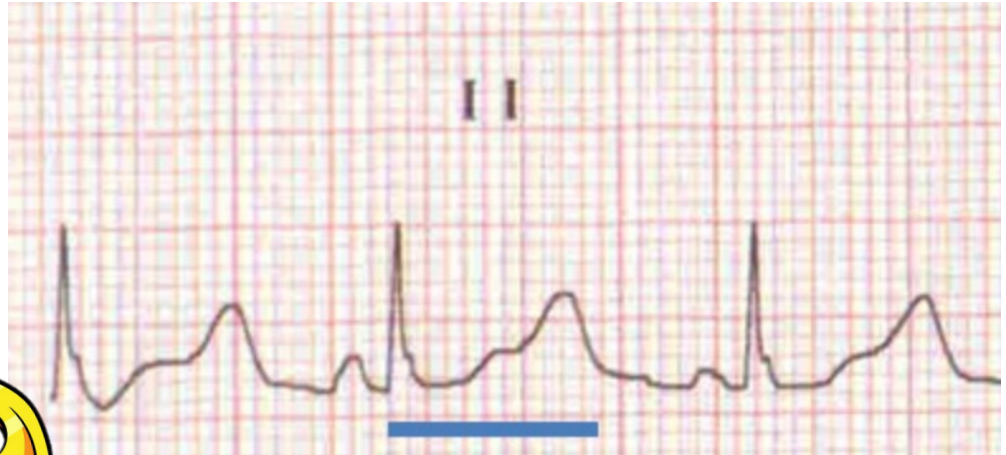QT PROLONGATION

QT >500MSEC

**SYNCOPE
W/STRESS**

PALPITATIONS

FAMILY HX!



CREDIBLEMEDS.ORG

ARRHYTHMOGENIC RIGHT VENTRICULAR CARDIOMYOPATHY (ARVC)

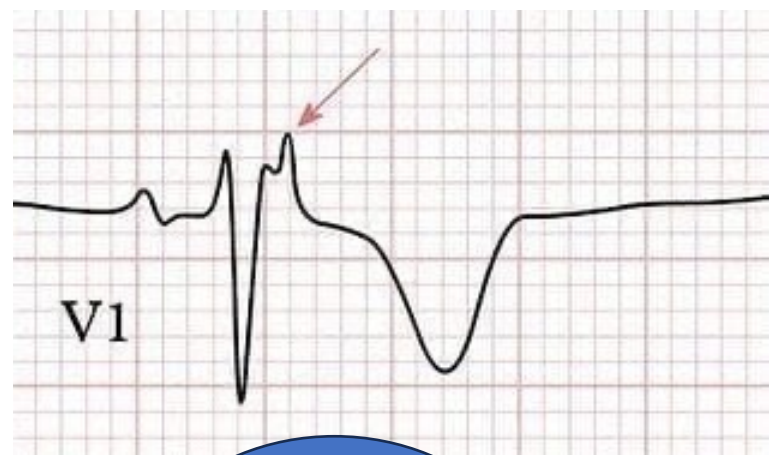
PALPITATIONS/ SYNCOPE

CHF

**ARRHYTHMIAS TRIGGERED
BY ADRENERGIC
STIMULATION**

RVOT DILATATION

EPSILON WAVE!



**NO
SPORTS!**

AICD

